



volpara[®] 
density[™]


Productivity | Compliance | Communication

> VolparaDensity Measures Breast Density

ACR BI-RADS® Definition


“2. SUCCINCT DESCRIPTION OF THE OVERALL BREAST COMPOSITION

This is an overall assessment of the volume of attenuating tissues in the breast”



Using science from Oxford, Nijmegen and Toronto, VolparaDensity provides you with estimates of the volumes of the different tissues in the breast direct from standard, “For Processing” digital mammograms: giving you 3D information for a 3D phenomenon, which is validated versus breast MRI.

Cleared by the FDA to also provide an ACR breast density category, VolparaDensity is in use at hundreds of sites globally, having analyzed millions of women.

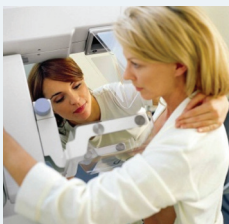


Volumetric Breast Density =

Volume of Fibroglandular Tissue in cm³

Volume of Breast in cm³

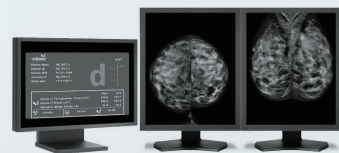> Clinical Workflow with VolparaDensity



DICOM “For Processing” mammograms are sent automatically to Volpara.



**volpara®
density™**



Breast density readings are automatically available within minutes of the last x-ray, on reader workstations and/or on compatible mammography reporting systems.

> The Patient Scorecard

volpara®

Patient Name: Patricia Roberts
 Patient ID: A1234
 Patient DOB: 01/01/1970
 Accession #: 12347
 Study Date: 01/01/2014

VDG®

Scale showing volumetric breast density thresholds and ACR breast density categories

VDG™/ACR breast density category visible in "thumbnail" mode*

	Right	Left
Volume of Fibroglandular Tissue (cm ³)	40.9	46.0
Volume of Breast (cm ³)	459.6	494.6
Volumetric Breast Density (%)	8.9	9.3

1.7 mGy 10.3 kPa 9.3%

Average radiation dose per image, using patient's density results

Average pressure applied using compression force/contact area

Higher volumetric density of left or right breast

Dose and pressure applied are available with the VolparaDoseRT™ module.

*Breast density category is configurable as "a, b, c, d" or "1, 2, 3, 4"

> The Clinical Scorecard

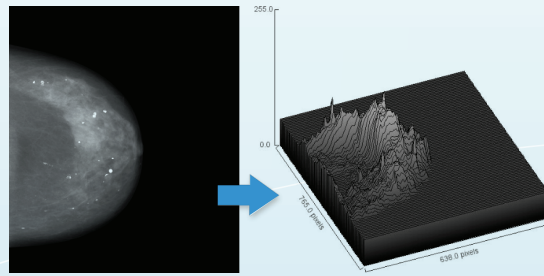
- Consistent density readings, no matter the mammography or tomosynthesis unit, or reader
- Improved productivity by reducing decision time needed
- Increased compliance with new laws
- Better communications with your clients, by offering a density consultation within minutes of the last x-ray

MULTI-VENDOR

> Importance of Density

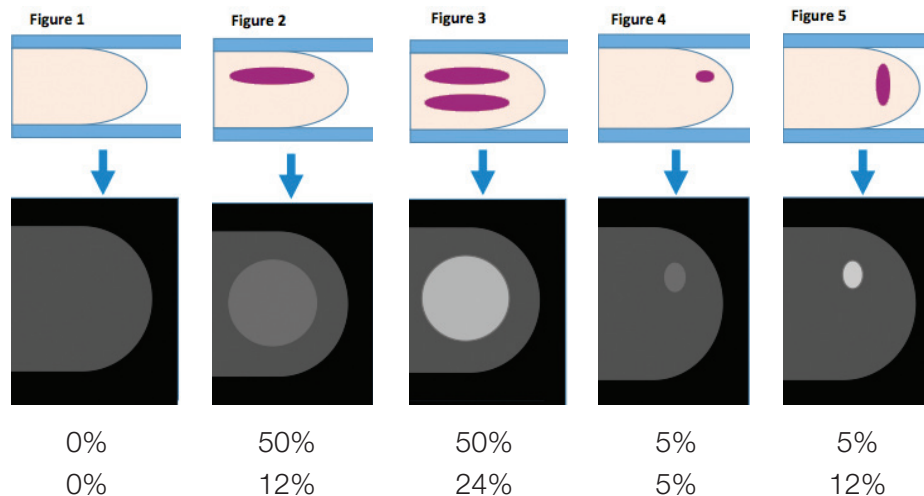
It is estimated that over 40 percent of women in the US who are of mammogram screening age have dense breast tissue. The volume and distribution of this dense breast tissue plays a major role in the sensitivity of screening mammography as well as the individual patient's risk of developing breast cancer:

- Mammography is estimated to be only 48% effective in dense breasts, compared to 98% effective in fatty breasts (DMIST trial).
- Women with extremely dense breasts are twice as likely to develop breast cancer as an average density woman.
- The risk associated with extremely dense breasts is similar to the risk associated with a family history of breast cancer in a mother, sister, or daughter.



> Volumetric Density

Volpara assesses breast composition at each pixel by calculating the x-ray attenuation between that pixel and the x-ray source and from that working out what kind of tissues must have been present. Volumetric breast density and visual assessment are strongly correlated, but the following examples show the benefits of a volumetric approach especially for focal lesions. The top figures here are side on views of a breast under compression, and the bottom views are the corresponding mammograms with their visual and volumetric breast density assessments.



> End User References

Please see our web-site www.volparasolutions.com for end user references.



US +1 855 607 0478
 EUROPE +44 203 051 1029
 REST OF WORLD +64 4 499 6029

EMAIL info@volparasolutions.com
 WEBSITE volparasolutions.com